

CLINICAL PRACTICE

Caren G. Solomon, M.D., M.P.H., *Editor*

Herniated Lumbar Intervertebral Disk

Richard A. Deyo, M.D., M.P.H., and Sohail K. Mirza, M.D., M.P.H.

This Journal feature begins with a case vignette highlighting a common clinical problem. Evidence supporting various strategies is then presented, followed by a review of formal guidelines, when they exist. The article ends with the authors' clinical recommendations.

A 41-year-old man reports the sudden onset of low back and left leg pain. The symptoms began while he was doing yard work and pulling out large bushes. Since the onset of the pain 2 days ago, it has worsened, although he took a single dose of ibuprofen when the pain began. The patient has no clinically significant medical history, and the physical examination is normal other than severe pain in the left leg with a straight-leg-raising maneuver to 40 degrees. He says, "I'm sure I slipped a disk," and he requests magnetic resonance imaging (MRI) of the low back. What testing and treatment would you recommend?

THE CLINICAL PROBLEM

LOW BACK PAIN AND LEG PAIN ARE COMMON SYMPTOMS. TWO THIRDS OF adults have back pain at some time in their lives, and approximately 10% of adults report back pain that has spread to below the knees within the previous 3 months.^{1,2} "Sciatica" refers to pain in a sciatic-nerve distribution, but this term is sometimes used indiscriminately to describe back and leg pain. Lumbar "radiculopathy" more specifically refers to pain with possible motor and sensory disturbances in a nerve-root distribution. After lumbar stenosis, spondylolisthesis, and fracture have been ruled out, approximately 85% of patients with sciatica are found to have a herniated intervertebral disk.³

Herniation, which refers to displacement of intervertebral disk material beyond the normal margins of the disk space, was initially described as disk "rupture."⁴ The disk material may include elements of the nucleus pulposus, annulus fibrosus, or both. Symptomatic herniation most often occurs in the posterolateral aspect of the disk, but midline herniations also occur. Disk-related radiculopathy appears to be both a biochemical and mechanical process. Contact of the nucleus pulposus with a nerve root provokes the inflammation that may be necessary in order for mechanical compression to cause pain.⁵ Disk herniation does not necessarily cause pain; MRI commonly shows herniated disks in asymptomatic persons, and the prevalence of herniated disks increases with age.⁶ Thus, symptoms may be misattributed to incidental MRI findings.

Both genetic and environmental factors may be important causes of disk herniation. Epidemiologic studies suggest that strenuous activities and cigarette smoking are risk factors.⁷ Studies of familial aggregation and studies involving twins suggest that genetic factors may confer a predisposition to disk degeneration and herniation; these factors may be related to the structure of collagen and other disk elements.⁸

From the Departments of Family Medicine, Medicine, and Public Health and Preventive Medicine, and the Oregon Institute of Occupational Health Sciences, Oregon Health and Science University, Portland (R.A.D.); and the Department of Orthopaedic Surgery and the Dartmouth Institute, Dartmouth Geisel School of Medicine, Hanover, NH (S.K.M.). Address reprint requests to Dr. Deyo at Oregon Health and Science University, 3181 SW Sam Jackson Park Rd., Mail Code FM, Portland, OR 97239, or at deyor@ohsu.edu.

N Engl J Med 2016;374:1763-72.

DOI: 10.1056/NEJMc1512658

Copyright © 2016 Massachusetts Medical Society.



**An audio version
of this article is
available at
NEJM.org**

KEY CLINICAL POINTS

HERNIATED LUMBAR INTERVERTEBRAL DISK

- Herniated lumbar disks are the leading cause of sciatica, but they also are detected on imaging (MRI or CT) in asymptomatic persons.
- The natural history of herniated lumbar disks is favorable. One study showed that without surgery, pain decreases in approximately 87% of patients within 3 months.
- MRI or CT is indicated in patients with persistent sciatica that lasts 4 to 6 weeks and in whom epidural glucocorticoid injections or surgery are being considered.
- Oral medications and supervised exercise provide slight relief of symptoms. Epidural glucocorticoid injections are an option for patients with severe persistent sciatica, but they do not reduce rates of subsequent surgery.
- Patients with severe or progressive neurologic deficits require a referral for surgery. Elective surgery is an option for patients with congruent clinical and MRI findings and a condition that does not improve within 6 weeks. The major benefit of surgery is relief of sciatica that is faster than relief with conservative treatment, but results of early surgical and prolonged conservative treatment tend to be similar at 1 year of follow-up. Patients and physicians should share in decision making.

The natural history of herniated lumbar disks is generally favorable, but patients with this condition have a slower recovery than those with nonspecific back pain. In one study involving patients with a herniated disk and no indication for immediate surgery, 87% who received only oral analgesics had decreased pain at 3 months.⁹ Even in randomized trials that enrolled patients with persistent sciatica, the condition of most patients who did not undergo surgery improved.^{10,11}

The condition of patients who have motor deficits corresponding to a single nerve root (such as weakness on dorsiflexion of the foot, or foot drop) associated with herniated disks also improves over time. In one study, 81% of patients with initial paresis had recovered without surgery after 1 year.¹² Sensory deficits may be more persistent; the rate of recovery is 50% at 1 year. MRI shows shrinkage of most herniated disks over time, and up to 76% partially or completely resolve by 1 year.¹³ However, recurrences of pain are common. In one study involving a cohort of persons who presented with sciatica, 25% of those whose sciatica resolved had a recurrence of symptoms within 1 year.¹⁴

(e.g., a history of cancer or trauma or the presence of fever) are usually apparent from the history and physical examination. Back pain may precede sciatica, but the pain and paresthesia of sciatica often become dominant, and the pain typically radiates to below the knee. Often there is no specific precipitating event; a “nonsudden” onset is common.¹⁵

Data obtained from the patient’s clinical history and physical examination are moderately accurate in establishing the diagnosis (Table 1).¹⁵⁻¹⁷ The straight-leg-raising test for nerve-root compression is widely used, and it is typically considered to be positive if sciatica is reproduced by elevating the leg to between 30 and 70 degrees.³ A positive ipsilateral straight-leg-raising test (in which the leg with sciatica is raised and pain is elicited on the side of the raised leg) is sensitive but not specific. In contrast, a positive crossed straight-leg-raising test (in which sciatica is reproduced by raising the opposite leg) is specific but not sensitive (Table 1).¹⁷

In two studies of surgery for sciatica, at least 95% of herniated disks were at the L4–L5 or L5–S1 levels.^{10,11} Thus, neurologic examination can focus on the L5 and S1 nerve roots (Fig. 1).¹⁸

Rarely, a massive midline disk herniation may compress the cauda equina; this is known as the cauda equina syndrome. This compression typically causes unilateral or bilateral sciatica, motor weakness, and urinary incontinence or retention. Saddle anesthesia (loss of sensation in the area of the buttocks, posterior superior thighs, and perineum) is characteristic, and anal sphincter tone may be diminished.¹⁹

STRATEGIES AND EVIDENCE

CLINICAL DIAGNOSIS

The differential diagnosis of sciatica includes conditions other than herniated disks. These conditions include tumors, a vertebral fracture, an epidural abscess, spondylolisthesis, lumbar stenosis, a synovial cyst or cysts, and herpetic and diabetic mononeuropathies.³ Clues to these conditions

Table 1. Estimated Accuracy of Findings on Clinical Assessment for Diagnosis of Nerve-Root Compression Due to a Herniated Disk, According to Either MRI or Surgical Findings.*

Assessment and Finding	Patient Sample	Reference Standard	Sensitivity	Specificity	Positive Predictive Value
					10% Prevalence 50% Prevalence percent
Clinical history†					
Leg pain worse than back pain	Referred from primary care to neurology	MRI	82	54	17 64
Typical dermatomal pattern of symptom distribution	Referred from primary care to neurology	MRI	89	31	13 56
Pain worse on coughing, sneezing, or straining	Referred from primary care to neurology	MRI	50	67	14 60
Physical examination‡					
Positive ipsilateral straight-leg-raising test	Primary care	MRI	64	57	14 60
Positive crossed straight-leg-raising test	Referred for surgery	Surgical findings	92	28	13 56
Paresis	Referred for surgery	Surgical findings	28	90	24 74
Muscle atrophy	Primary care	MRI	27	93	30 79
Impaired reflexes§	Referred for surgery	Surgical findings	15–38	50–94	3–41 23–86
Neurologist's assessment based on clinical history and physical examination¶					
	Primary care	MRI	15	93	19 68
	Referred from primary care to neurology	MRI	81	52	16 63

* Estimates vary substantially among studies, in part because of varying patient selection criteria and procedures. The prevalence of a herniated disk as the cause of back and leg pain may be approximately 10% in primary care and 50% in specialty care. MRI denotes magnetic resonance imaging.
 † Data on clinical history are calculated from the data in a study by Vroomen et al.¹⁶ That study included patients with back and leg pain. MRI showed herniated disk and nerve-root compression in 152 patients, and 122 patients had other diagnoses.
 ‡ Estimates are based on data from a systematic review of multiple studies by van der Windt et al.¹⁷
 § The L5 nerve root affects neither the Achilles tendon nor the patellar tendon in a person with suspected L5 radiculopathy. normal reflexes convey no information.




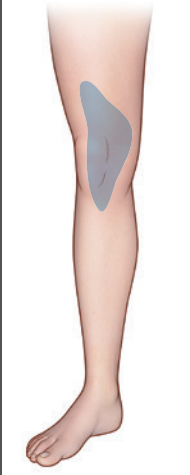
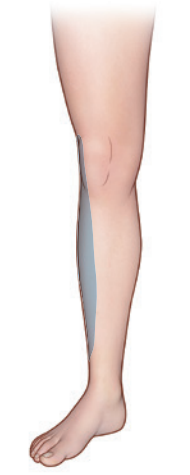
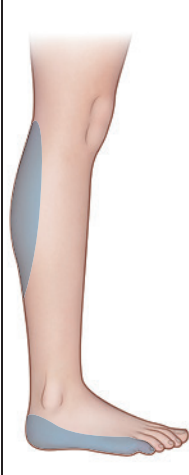
	Nerve Root		
	L4	L5	S1
Pain			
Numbness			
Motor weakness	Extension of quadriceps	Dorsiflexion of great toe and foot	Plantar flexion of great toe and foot
Screening examination	Squatting and rising	Walking on heels	Walking on toes
Reflexes	Knee jerk diminished	None reliable	Ankle jerk diminished

Figure 1. Testing for Compromise of a Lumbar Nerve Root.

The screening examination that focuses on the L4 nerve root assesses whether the patient has difficulty with squatting and then rising from a squatting position. The examination that focuses on the L5 nerve root assesses whether the patient is unable to maintain foot dorsiflexion while walking on the heels, and the examination that focuses on the S1 nerve root assesses whether the patient is unable to maintain foot plantar flexion while walking on the toes. Adapted from Bigos et al.¹⁸

DIAGNOSTIC TESTS

Plain radiography does not show herniated disks, but it helps to rule out a tumor or fracture, infec-

tion, and spondylolisthesis. Most guidelines recommend the use of plain radiography only in patients who have a high risk of underlying systemic disease (e.g., a history of cancer) and patients who use injection drugs or receive oral or parenteral glucocorticoids.²⁰

Computed tomography (CT) or MRI can confirm a clinical diagnosis of a herniated disk. Early MRI is indicated in patients with progressive or severe deficits (e.g., multiple nerve roots) or clinical findings that suggest an underlying tumor or infection (e.g., findings that indicate injection-drug use or fever). Otherwise, CT or MRI is necessary only in a patient whose condition has not improved over 4 to 6 weeks with conservative treatment and who may be a candidate for epidural glucocorticoid injections or surgery.

On imaging, disk bulging is common among asymptomatic persons (in approximately 60% of persons at 50 years of age), as is disk protrusion (in 36% of persons at 50 years of age).⁶ Thus, there is a substantial risk of misleading MRI findings, and an ill-advised cascade of subsequent testing and intervention may result.²¹ We therefore do not recommend the routine use of CT or MRI.

CT and MRI terminology was inconsistent in the past, but a consensus now distinguishes among disk bulging, protrusion, extrusion, and sequestration (Fig. 2). The latter three terms define a herniated disk, whereas bulging does not.²² Extrusion and sequestration are most likely to cause radicular symptoms.

Electromyography is usually unnecessary. However, it may be helpful in patients with ambiguous symptoms or findings on examination and CT or MRI.

CONSERVATIVE THERAPY

Cohort studies suggest that the condition of many patients with a herniated lumbar disk improves in 6 weeks; thus, conservative therapy is generally recommended for 6 weeks in the absence of a major neurologic deficit. In one study, 36% of patients reported improvement in their condition at 2 weeks, and this percentage increased substantially with longer follow-up.²³ Furthermore, persistent pain after 6 weeks of conservative therapy has been the entry criterion in most randomized trials of disk surgery.^{10,11}

The favorable natural history of sciatica may explain why certain treatments that have not proved to be effective in clinical trials have been

Figure 2. CT and MRI Terminology for Herniated Disks.

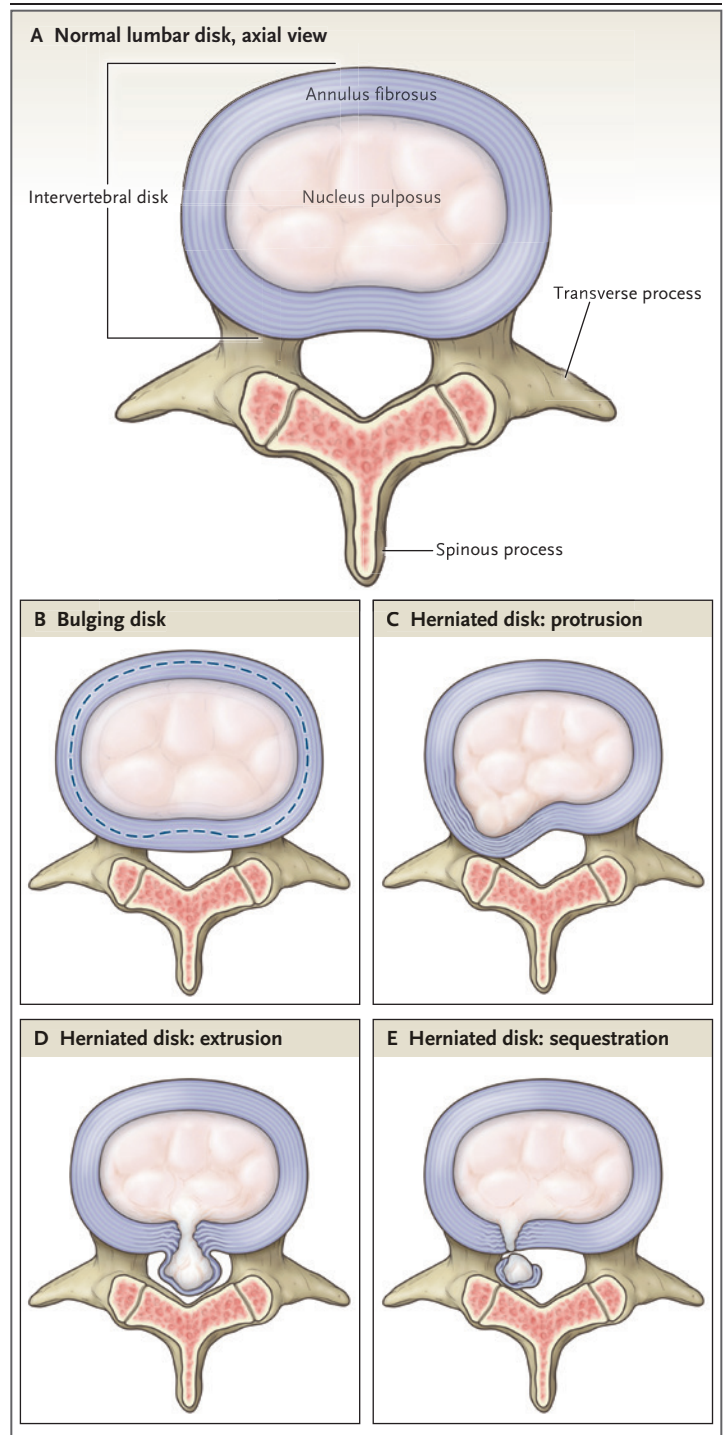
Panel A shows a normal lumbar intervertebral disk. Panel B shows a bulging disk. The dashed line indicates the normal disk space. Annular tissue extends beyond the normal disk space. Panel C shows protrusion of a disk. The greatest measure of the displaced material is less than the measure of the base of the displaced material. Panel D shows extrusion of a herniated disk. The greatest measure of the displaced disk material is greater than the measure of the base of the displaced disk material. Panel E shows sequestration of a herniated disk. The displaced disk material has lost all connection with the disk of origin. Adapted from Fardon et al.²²

perceived as being effective. For example, randomized trials have not shown that recovery from sciatica⁹ or back pain²⁴ is faster with bed rest than with watchful waiting. Similarly, a meta-analysis of 32 randomized trials (16 of which were judged to have a low risk of bias) showed no significant benefit of lumbar traction over sham therapy with respect to pain relief, improved function, or reduced absenteeism from work.²⁵

There is no evidence that conservative treatments change the natural history of disk herniation, but some offer slight relief of symptoms. Nonsteroidal antiinflammatory drugs (NSAIDs) reduce back pain somewhat in the short term, but they have a less clear benefit in patients with sciatica.²⁶ The few randomized trials of NSAIDs for sciatica are generally of low quality,²⁶ and trials to assess the use of acetaminophen in patients with sciatica are lacking.

Randomized trials show no significant advantage of systemic glucocorticoid therapy over placebo with respect to pain relief or reduced rates of subsequent surgical intervention, and they show little, if any, advantage with respect to improvement in physical function.^{27,28} Adverse effects, including insomnia, nervousness, and increased appetite, are common. There is insufficient evidence to judge the efficacy of antiepileptic drugs, antidepressants, or muscle relaxants in patients with sciatica.²⁶

Data from randomized trials to support the use of opioids in patients with sciatica are lacking.²⁶ Systematic reviews suggest that opioids have slight short-term benefits with respect to reduced back pain.²⁹ Convincing evidence of benefits of long-term use is lacking, and there is growing concern regarding serious long-term adverse effects such as fractures and opioid overdose and



abuse.³⁰ The use of opioids should be limited to patients with severe pain and should be time-limited from the outset.

The use of epidural glucocorticoid injections in patients with herniated disks has increased rapidly in recent years, although these injections

are used on an off-label basis. A systematic review showed that patients with radiculopathy who received epidural glucocorticoid injections had slightly better pain relief (by 7.5 points on a 100-point scale) and functional improvement at 2 weeks than patients who received placebo. There were no significant advantages at later follow-up and no effect on long-term rates of surgery.³¹ Procedural complications are rare, but neurologic events such as paraplegia have been reported, and the Food and Drug Administration recently required a warning on product labels for glucocorticoids. Systemic side effects, including cortisol suppression³² and osteopenia,³³ may also occur.

In patients with acute disk herniations, avoidance of prolonged inactivity in order to prevent debilitation is important. Most patients can be encouraged to stand and walk. The ability to sit comfortably is a sign of improvement in the patient's condition and suggests that more structured exercise can be undertaken. Evidence regarding the effects of physical therapy and exercise is limited. A systematic review of five randomized trials showed that patients who participated in supervised exercise had greater short-term pain relief than patients who received counseling alone, but this reduction in pain was small and these patients did not have a long-term benefit with respect to reduced pain or disability.³⁴

A randomized trial of chiropractic manipulation for subacute or chronic "back-related leg pain" (without confirmation of nerve-root compression on MRI) showed that manipulation was more effective than home exercise with respect to pain relief at 12 weeks (by a mean 1-point decrease on a pain-intensity scale on which scores ranged from 0 to 10, with higher scores indicating greater severity of pain) but not at 1 year.³⁵ In addition, a randomized trial involving patients who had acute sciatica with MRI-confirmed disk protrusion showed that at 6 months, significantly more patients who underwent chiropractic manipulation had an absence of pain than did those who underwent sham manipulation (55% vs. 20%).³⁶ Neurologic complications in the lumbar spine, including worsened disk herniation or the cauda equina syndrome, have been reported anecdotally, but they appear to be extremely rare.³⁵⁻³⁷

SURGERY

Wide geographic variations in rates of spinal surgery have aroused concern about overuse of spi-

nal surgery in some areas.³⁸ Unless patients have major neurologic deficits, surgery is generally appropriate only in those who have nerve-root compression that is confirmed on CT or MRI, a corresponding sciatica syndrome, and no response to 6 weeks of conservative therapy. The major benefit of surgery is that relief of sciatica is faster than relief with conservative therapy, but, on average, there is a smaller advantage of surgery with respect to the magnitude of relief of back pain.^{10,11} North American Spine Society guidelines note that, on average, patients with signs of psychological distress such as somatization or depression have worse surgical outcomes than those who do not have these signs, and patients with a positive straight-leg-raising test have better surgical outcomes than those with negative results on this test.³⁹

Several randomized trials have compared surgery with conservative treatment for herniated lumbar disks. These trials included patients with minor neurologic deficits but not major or progressive deficits (for whom delaying surgery is ill-advised). All the trials involved the use of open discectomy or microdiscectomy. Conservative care was not standardized, but it included at least the use of pain medication and physical therapy. None of the trials were blinded (i.e., none required sham surgery), so bias owing to patient expectations was possible. Each trial had substantial crossover between the conservative group and the surgical group; this may have "diluted" a benefit of surgery.

These trials have consistently shown faster relief of pain with surgery than with conservative treatment. However, most,^{10,11,40,41} although not all,⁴² trials showed no significant advantage of surgery over conservative treatment with respect to relief of sciatica at 1 to 4 years of follow-up. For example, in one trial,¹⁰ the median time to resolution of symptoms was 4 weeks with early surgery and 12 weeks with prolonged conservative therapy; at 1 year, 5% of patients in each group had not recovered.¹⁰ In patients assigned to conservative treatment who later crossed over to the surgical group, the results of surgery were similar to those in patients who underwent earlier surgery; this suggests the absence of a therapeutic window for surgery that closed quickly.¹⁰ Recovery from mild motor deficits occurred in most patients with or without surgery.¹⁰⁻¹²

Given these results, either surgery or conser-

vative treatment may be a reasonable option, depending on the patient's preferences for immediate pain relief, how averse the patient is to surgical risks, and other considerations. Thus, shared decision making involving both patients and physicians is valuable; meaningful involvement requires that patients be well informed about these options and their associated benefits and risks. In one randomized trial, patients with a herniated disk who saw a computer-based decision aid were less likely to choose surgery than those who received conventional written materials. Despite between-group differences with respect to rates of surgery, there were no significant differences in outcomes at 1 year of follow-up.⁴³

Several discectomy techniques are available (Fig. 3). With the emergence of microdiscectomy (see the video) and minimally invasive techniques, there has been a striking shift from inpatient to ambulatory surgery. Patients may return to work quickly even after they have undergone open discectomy. In a case series involving patients who had no restrictions on activity after surgery, one third returned to work within 1 week, and 97% returned to work by 8 weeks. The interval between surgery and return to full duty was longer in patients with physically strenuous occupations.⁴⁴

Procedural complications of lumbar discectomy are less common than procedural complications of other types of spine surgery. A registry study indicated that an estimated 0.6 deaths per 1000 procedures had occurred at 60 days after the procedure.⁴⁵ New or worsening neurologic deficits occur in 1 to 3% of patients, direct nerve-root injury occurs in 1 to 2%, and wound complications (e.g., infection, dehiscence, and seroma) occur in 1 to 2%.⁴⁶ Incidental durotomy, which occurs in approximately 3% of patients, is associated with increases in the duration of surgery, blood loss during surgery, and the length of inpatient stay,⁴⁷ as well as potential long-term effects such as headache. All tissues at the surgical site heal with some scarring, which contracts and binds nerves to surrounding structures. Normally, nerve roots glide a few millimeters in the neuroforamen with each walking step. Stretch of tethered nerves may be one source of chronic postsurgical pain.

Repeat operations, for a variety of reasons, occur in approximately 6% of patients after 1 year and in approximately 13% of patients after 4 years⁴⁸; rates vary substantially according to the surgeon.

Even after adjustment for patient demographic factors and coexisting conditions, rates of reoperation at 4 years in one state varied from 10% to 19%; this suggests variability in patient selection, quality of care, and surgical skill.⁴⁸

AREAS OF UNCERTAINTY

Data from epidemiologic studies and biomechanical models suggest that lifestyle modifications such as smoking cessation, weight loss, and regular exercise may prevent sciatica or help to reduce its recurrence. However, we are unaware of relevant randomized trials. There is insufficient evidence to make a recommendation regarding acupuncture for sciatica.

An inflammatory component to lumbar radiculopathy has been recognized, and anticytokine therapy has been proposed. Limited clinical-trial data have been inconsistent, and this approach remains experimental.⁴⁹



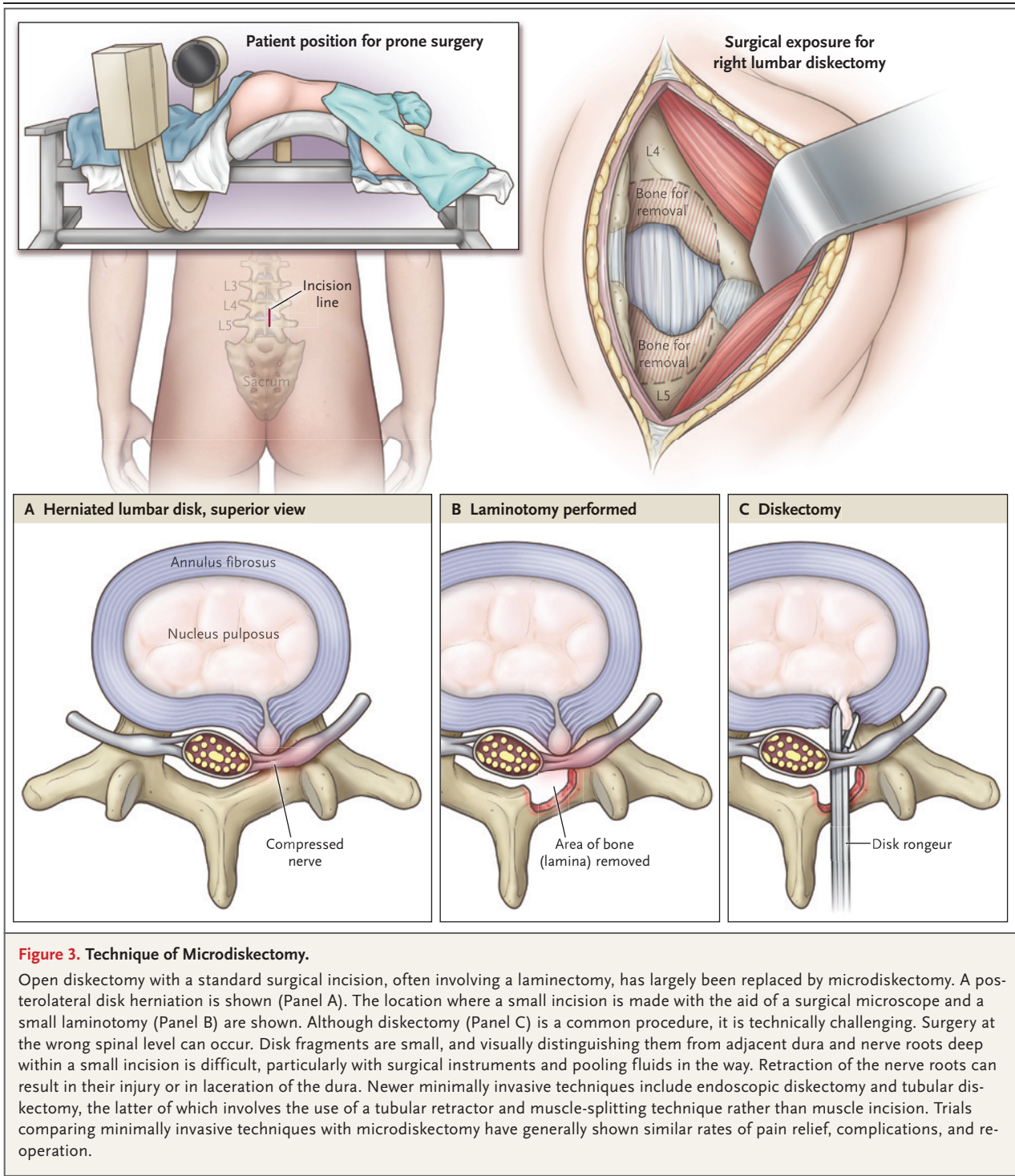
A video showing a microdiscectomy is available at NEJM.org

GUIDELINES

A guideline from the American College of Physicians recommends the use of CT or MRI in patients without severe neurologic deficits only if they are candidates for surgery or epidural glucocorticoid injections after a 1-month trial of conservative therapy.²⁰ An American Pain Society guideline recommends epidural glucocorticoid injections as an option for patients with persistent radiculopathy due to a herniated disk, with shared decision making and consideration of the inconsistent evidence, moderate short-term benefits, and lack of long-term benefits associated with this treatment. It similarly recommends shared decision making regarding surgery.⁵⁰ The recommendations in this review are generally concordant with the guidelines of the American College of Physicians, the American Pain Society, and the North American Spine Society.³⁹

CONCLUSIONS AND RECOMMENDATIONS

The patient described in the vignette presents with back and leg pain and a positive straight-leg-raising test that suggests a herniated disk. Patients should be reassured regarding the favorable prognosis of herniated disks with sciatica. Clinicians should avoid the use of frightening terms such as



“ruptured disk” (which implies severe tissue damage) in favor of terms such as “protruded” disk.

Conservative therapy for 6 weeks, often including NSAIDs and exercise-based physical therapy, is appropriate for most patients in the absence

of severe neurologic deficits, and we would recommend this approach for the patient described. The use of CT or MRI should be discouraged unless the symptoms do not decrease over 4 to 6 weeks and the patient is considered to be a

candidate for epidural glucocorticoid injections or surgery, at which point MRI would be the best test for diagnostic confirmation and surgical planning. Epidural glucocorticoid injections may offer temporary relief in patients with the most severe pain.

In patients with pain that persists beyond 6 weeks and symptoms, findings on examination, and MRI results that are congruent, surgery is an option. Patients and physicians should be engaged in shared decision making regarding surgery, with attention to potential risks and bene-

fits. Patients should be informed that relief of leg pain will probably be faster with surgery than with conservative therapy, that later surgery remains an option if they continue to receive conservative care, and that by 1 year, outcomes of early surgery generally do not differ from those of prolonged conservative therapy.

Dr. Deyo reports receiving a financial award from NuVasive as part of a lifetime achievement award from the International Society for the Study of the Lumbar Spine. No other potential conflict of interest relevant to this article was reported.

Disclosure forms provided by the authors are available with the full text of this article at NEJM.org.

REFERENCES

- Lawrence RC, Felson DT, Helmick CG, et al. Estimates of the prevalence of arthritis and other rheumatic conditions in the United States. Part II. *Arthritis Rheum* 2008;58:26-35.
- Andersson G, Watkins-Casatillo SI. Low back pain. In: *The burden of musculoskeletal diseases in the United States*, third edition. Rosemont, IL: Bone and Joint Initiative, 2014 (<http://www.boneandjointburden.org>).
- Ropper AH, Zafonte RD. Sciatica. *N Engl J Med* 2015;372:1240-8.
- Mixer WJ, Barr JS. Rupture of the intervertebral disc with involvement of the spinal canal. *N Engl J Med* 1934;211:210-5.
- Rhee JM, Schaufele M, Abdu WA. Radiculopathy and the herniated lumbar disc: controversies regarding pathophysiology and management. *J Bone Joint Surg Am* 2006;88:2070-80.
- Brinjikji W, Luetmer PH, Comstock B, et al. Systematic literature review of imaging features of spinal degeneration in asymptomatic populations. *AJNR Am J Neuroradiol* 2015;36:811-6.
- Sørensen IG, Jacobsen P, Gyntelberg F, Suadicani P. Occupational and other predictors of herniated lumbar disc disease—a 33-year follow-up in the Copenhagen male study. *Spine* 2011;36:1541-6.
- Battié MC, Videman T, Parent E. Lumbar disc degeneration: epidemiology and genetic influences. *Spine* 2004;29:2679-90.
- Vroomen PCAJ, de Krom MCTFM, Wilmink JT, Kester ADM, Knottnerus JA. Lack of effectiveness of bed rest for sciatica. *N Engl J Med* 1999;340:418-23.
- Peul WC, van Houwelingen HC, van den Hout WB, et al. Surgery versus prolonged conservative treatment for sciatica. *N Engl J Med* 2007;356:2245-56.
- Weinstein JN, Tosteson TD, Lurie JD, et al. Surgical vs nonoperative treatment for lumbar disk herniation: the Spine Patient Outcomes Research Trial (SPORT): a randomized trial. *JAMA* 2006;296:2441-50.
- Overvest GM, Vleggeert-Lankamp CL, Jacobs WC, Brand R, Koes BW, Peul WC. Recovery of motor deficit accompanying sciatica — subgroup analysis of a randomized controlled trial. *Spine J* 2014;14:1817-24.
- Bush K, Cowan N, Katz DE, Gishen P. The natural history of sciatica associated with disc pathology: a prospective study with clinical and independent radiologic follow-up. *Spine* 1992;17:1205-12.
- Suri P, Rainville J, Hunter DJ, Li L, Katz JN. Recurrence of radicular pain or back pain after nonsurgical treatment of symptomatic lumbar disk herniation. *Arch Phys Med Rehabil* 2012;93:690-5.
- Verwoerd AJ, Peul WC, Willemsen SP, et al. Diagnostic accuracy of history taking to assess lumbosacral nerve root compression. *Spine J* 2014;14:2028-37.
- Vroomen PC, de Krom MC, Wilmink JT, Kester AD, Knottnerus JA. Diagnostic value of history and physical examination in patients suspected of lumbosacral nerve root compression. *J Neurol Neurosurg Psychiatry* 2002;72:630-4.
- van der Windt DA, Simons E, Riphagen II, et al. Physical examination for lumbar radiculopathy due to disc herniation in patients with low-back pain. *Cochrane Database Syst Rev* 2010;2:CD007431.
- Bigos SJ, Bowyer OR, Braen GR, et al. Acute low back problems in adults: assessment and treatment — quick reference guide number 14. Rockville, MD: Department of Health and Human Services, Public Health Service, Agency for Health Care Policy and Research, December 1994 (<http://www.ncbi.nlm.nih.gov/books/NBK52120/>).
- Fairbank J, Hashimoto R, Dailey A, Patel AA, Dettori JR. Does patient history and physical examination predict MRI proven cauda equina syndrome? *Evid Based Spine Care J* 2011;2:27-33.
- Chou R, Qaseem A, Owens DK, Shekelle P. Diagnostic imaging for low back pain: advice for high-value health care from the American College of Physicians. *Ann Intern Med* 2011;154:181-9.
- Webster BS, Choi Y, Bauer AZ, Cifuentes M, Pransky G. The cascade of medical services and associated longitudinal costs due to nonadherent magnetic resonance imaging for low back pain. *Spine (Phila Pa 1976)* 2014;39:1433-40.
- Fardon DF, Williams AL, Dohring EJ, Murtagh FR, Gabriel Rothman SL, Sze GK. Lumbar disc nomenclature: version 2.0: recommendations of the combined task forces of the North American Spine Society, the American Society of Spine Radiology and the American Society of Neuroradiology. *Spine J* 2014;14:2525-45.
- Vroomen PCAJ, de Krom MCTFM, Knottnerus JA. Predicting the outcome of sciatica at short-term follow-up. *Br J Gen Pract* 2002;52:119-23.
- Deyo RA, Diehl AK, Rosenthal M. How many days of bed rest for acute low back pain? *N Engl J Med* 1986;315:1064-70.
- Wegner I, Widyahening IS, van Tulder MW, et al. Traction for low-back pain with or without sciatica. *Cochrane Database Syst Rev* 2013;8:CD003010.
- Pinto RZ, Maher CG, Ferreira ML, et al. Drugs for relief of pain in patients with sciatica: systematic review and meta-analysis. *BMJ* 2012;344:e497.
- Roncoroni C, Baillet A, Durand M, Gaudin P, Juvin R. Efficacy and tolerance of systemic steroids in sciatica: a systematic review and meta-analysis. *Rheumatology (Oxford)* 2011;50:1603-11.
- Goldberg H, Firtch W, Tyburski M, et al. Oral steroids for acute radiculopathy due to a herniated lumbar disk: a randomized clinical trial. *JAMA* 2015;313:1915-23.
- Chaparro LE, Furlan AD, Deshpande A, Mailis-Gagnon A, Atlas S, Turk DC. Opioids compared with placebo or other treatments for chronic low back pain: an update of the Cochrane Review. *Spine (Phila Pa 1976)* 2014;39:556-63.
- Chou R, Turner JA, Devine EB, et al. The effectiveness and risks of long-term opioid therapy for chronic pain: a systematic review for a National Institutes of

- Health Pathways to Prevention Workshop. *Ann Intern Med* 2015;162:276-86.
31. Chou R, Hashimoto R, Friedly J, et al. Epidural corticosteroid injections for radiculopathy and spinal stenosis: a systematic review and meta-analysis. *Ann Intern Med* 2015;163:373-81.
 32. Friedly JL, Comstock BA, Turner JA, et al. A randomized trial of epidural glucocorticoid injections for spinal stenosis. *N Engl J Med* 2014;371:11-21.
 33. Al-Shoha A, Rao DS, Schilling J, Peterson E, Mandel S. Effect of epidural steroid injection on bone mineral density and markers of bone turnover in postmenopausal women. *Spine* 2012;37(25):E1567-71.
 34. Fernandez M, Hartvigsen J, Ferreira ML, et al. Advice to stay active or structured exercise in the management of sciatica: a systematic review and meta-analysis. *Spine (Phila Pa 1976)* 2015;40:1457-66.
 35. Bronfort G, Hondras MA, Schulz CA, Evans RL, Long CR, Grimm R. Spinal manipulation and home exercise with advice for subacute and chronic back-related leg pain: a trial with adaptive allocation. *Ann Intern Med* 2014;161:381-91.
 36. Santilli V, Beghi E, Finucci S. Chiropractic manipulation in the treatment of acute back pain and sciatica with disc protrusion: a randomized double-blind clinical trial of active and simulated spinal manipulations. *Spine J* 2006;6:131-7.
 37. Oliphant D. Safety of spinal manipulation in the treatment of lumbar disk herniations: a systematic review and risk assessment. *J Manipulative Physiol Ther* 2004;27:197-210.
 38. Weinstein JN, Lurie JD, Olson PR, Bronner KK, Fisher ES. United States trends and regional variations in lumbar spine surgery: 1992-2003. *Spine* 2006;31:2707-14.
 39. Kreiner DS, Hwang SW, Easa JE, et al. An evidence-based clinical guideline for the diagnosis and treatment of lumbar disc herniation with radiculopathy. *Spine J* 2014;14:180-91.
 40. Weber H. Lumbar disc herniation: a controlled, prospective study with ten years of observation. *Spine (Phila Pa 1976)* 1983;8:131-40.
 41. Osterman H, Seitsalo S, Karppinen J, Malmivaara A. Effectiveness of microdiscectomy for lumbar disc herniation: a randomized controlled trial with 2 years of follow-up. *Spine* 2006;31:2409-14.
 42. Lurie JD, Tosteson TD, Tosteson AN, et al. Surgical versus nonoperative treatment for lumbar disc herniation: eight-year results for the spine patient outcomes research trial. *Spine (Phila Pa 1976)* 2014;39:3-16.
 43. Deyo RA, Cherkin DC, Weinstein J, Howe J, Ciol M, Mulley AG Jr. Involving patients in clinical decisions: impact of an interactive video program on use of back surgery. *Med Care* 2000;38:959-69.
 44. Carragee EJ, Han MY, Yang B, Kim DH, Kraemer H, Billyis J. Activity restrictions after posterior lumbar discectomy: a prospective study of outcomes in 152 cases with no postoperative restrictions. *Spine* 1999;24:2346-51.
 45. Smith JS, Saulle D, Chen CJ, et al. Rates and causes of mortality associated with spine surgery based on 108,419 procedures: a review of the Scoliosis Research Society Morbidity and Mortality Database. *Spine* 2012;37:1975-82.
 46. Shriver MF, Xie JJ, Tye EY, et al. Lumbar microdiscectomy complication rates: a systematic review and meta-analysis. *Neurosurg Focus* 2015;39(4):E6.
 47. Desai A, Ball PA, Bekelis K, et al. Outcomes after incidental durotomy during first-time lumbar discectomy. *J Neurosurg Spine* 2011;14:647-53.
 48. Martin BI, Mirza SK, Flum DR, et al. Repeat surgery after lumbar decompression for herniated disc: the quality implications of hospital and surgeon variation. *Spine J* 2012;12:89-97.
 49. Cohen SP, White RL, Kurihara C, et al. Epidural steroids, etanercept, or saline in subacute sciatica: a multicenter, randomized trial. *Ann Intern Med* 2012;156:551-9.
 50. Chou R, Loeser JD, Owens DK, et al. Interventional therapies, surgery, and interdisciplinary rehabilitation for low back pain: an evidence-based clinical practice guideline from the American Pain Society. *Spine (Phila Pa 1976)* 2009;34:1066-77.

Copyright © 2016 Massachusetts Medical Society.